

GANGRENOUS MASTITIS IN COWS: PATHOLOGICAL, MICROBIOLOGICAL AND SURGICOTHERAPEUTICAL INVESTIGATION

M. N. ISLAM¹, M. F. HOQUE², U. K. RIMA², B. Z. FATEMA², F. B. AZIZ³, M. I. FARUK² AND M. R. AKTER⁴

¹Department of Pathology & Parasitology, ²Department of Medicine, Surgery & Obstetrics, ³Department of Physiology and Pharmacology, ⁴Department of Microbiology, Hajee Mohammad Danesh Science and Technology University, Dinajpur, Bangladesh

Accepted for publication: November 27, 2008

ABSTRACT

Islam M. N., Hoque M. F., Rima U. K., Fatema B. Z., Aziz F. B., Faruk M. I. and Akter M. R. 2008. *Gangrenous Mastitis in Cows: Pathological, Microbiological and Surgicotherapeutical Investigation*. J. Soil. Nature. 2(3): 29-36

Gangrenous mastitis in cows was investigated at Dinajpur district of Bangladesh. The animals brought to clinics for the diagnosis and treatments were examined clinically, pathomicrobiologically and surgicotherapeutically. Out of 29 mastitis cases, only 7 cases of gangrenous mastitis were recorded. The signs, lesions and the causative organisms were characterized clinically, pathologically and bacteriologically, respectively and the surgicotherapeutical responses of the patients were noted. A presumptive diagnosis was done based on the identification of the organisms by preparing impression smears stained with Gram's stain. The organisms were finally isolated and identified by culturing and biochemical properties of the organisms in differential sugar media without typification. The animal was accepted for the amputation of the gangrenous portion (s) despite of the doubtful negative prognosis. The amputated tissues, exudates and the milk samples were collected taking necessary precautions for bacteriological as well as gross and histopathological examinations. The formalin fixed tissues were processed, sectioned and stained with haematoxylin and eosin for the histopathological examination. Possible all measures were taken carefully during the course of surgical operation giving emphasis on to less painful operation, check more bleeding, compensate fluid and electrolytes loss, provide hygienic measurement to avoid contamination and complications, and also taken necessary postoperative care. Both local and systemic signs of the disease were recorded and characterized clinically as anorexia, moderate elevation of the body temperature, dehydration, depression, reluctant to walk. The lesions were morphopathologically characterized as extremely swollen, bluish discoloration, foul smelling, serosanguineous odoriferous exudation, painless and cool to touch that indicated the development of moist gangrenous mastitis. The causative organisms (*Staphylococci*, *Bacilli*, and *E. coli*) were isolated and identified. The remarkable histopathological lesions were characterized as necrosis and sloughed off alveolar lining epithelium, pink stained proteinaceous exudates in ductal lumen, erosion and ulceration in the ductal system. All animals were recovered within different periods of time except one which was died during the course of treatment. The present study was conducted to investigate the gangrenous mastitis in cows based on the findings as stated above as well as to see the prognosis of the disease managed with surgicotherapeutical means.

Keywords: Mastitis, gangrene, gangrenous mastitis in cows

INTRODUCTION

Mastitis is an economically important disease and the common cause of culling of dairy cows. The disease causes irreparable injury to the udder by damaging the alveolar epithelium through inducing inflammation and is found throughout the world including Bangladesh. Clinical mastitis is divided into 4 categories: peracute, acute, sub-acute, and subclinical (Fraser *et al.*, 1998). The vast majority of organisms responsible for bovine mastitis are bacteria.

The causative organisms persist in the environment as well as in the udder in latent. The hidden organisms in the udder may flare up to produce clinical mastitis (Radostits *et al.*, 2000). Early detection of subclinical mastitis by somatic cell count and bacterial load count is important to combat the development of clinical mastitis. But the lacking of early diagnosis and farmer's awareness, the approximately curable mastitis progress to gangrenous ones which are mainly caused by *Staphylococcus aureus* and *Escherichia coli* (Jubb and Kennedy, 1963). *Staphylococcus aureus* and *Clostridium perfringens* were also isolated from the gangrenous mastitis. The severest form of the staphylococcal mastitis is the gangrenous form.

Gangrenous mastitis is developed by severe acute inflammation, with classical signs of heat, redness, swelling and pain, progress to necrosis with coldness of the affected area, blue black colour, fluid exudation, and crepitation. The lesions are histopathologically characterized as progressive swelling, vascular degeneration, and focal erosion and ulceration occur throughout the ductal system (Carlton and McGavin, 1995). Treatment of gangrenous mastitis is very difficult and possible by amputation of the gangrenous quarter (s) only to save the patient's life despite of doubtful prognosis. Therefore, this study was conducted to investigate the gangrenous mastitis, identify the causative organisms, clinicopathologically characterization of the signs and lesions, and to see the prognosis of the mastectomized patients suffering from the naturally occurring gangrenous mastitis.

MATERIALS AND METHODS

Clinical history

The detail patient's history in connection with the production performances, hygienic condition of the houses, colour and consistence of the milk, sedimentation in the milk, health status, recurrences, amount and quality of feed and water, previous disease condition, if any, was recorded and the characteristic clinical signs were studied systematically. The presented information and the development of signs were correlated and characterized according to the degree of severity of the disease. The lesion was examined carefully; the patients were categorized clinically and were accepted for the treatment following amputation of the affected quarter (s) considering all capable measurements.

Microbiological findings

Samples and Media

The amputated udder tissues and exudates of the affected cows were collected taking necessary precautions for the bacteriological examination. Nutrient agar, blood agar, Staphylococcus Media No. 110, MacConkey agar, Eosin Methylene Blue (EMB) agar, *Salmonella-Shigella* (SS) agar media and different sugar media were included to study the biochemical characteristics of the bacteria.

Gram's staining

Impression smears taken from the collected samples was stained with Gram's stain (McLeod *et al.*, 1981) to study the morphological and staining characteristics of bacteria and to provide information about the presumptive bacterial identification as per recommendation of Cowan (1985).

Culture and isolation of the organisms

Each of the samples was divided and inoculated separately in nutrient agar and blood agar to promote growth of bacteria. Each group of these media was incubated at optimal temperature for overnight. The colonies were subcultured to obtain pure culture with homogenous colonies.

Biochemical tests

The biochemical properties of the bacteria were detected and were presented in Table 3. The isolates were allowed to react with five basic sugars (dextrose, maltose, lactose, sucrose and mannitol) including catalase, indol production and Methyl-red tests. Their fermentation with acid and gas producing capacity was studied.

Identification of bacterial isolates

Bacterial isolates were identified by their cultural, morphological and biochemical characters. For the cultural characteristics, discrete colonies on the agar surface were observed. Their shape, size, consistency and colour were studied. Gram stained slides of the isolates were examined microscopically to study their morphology. The biochemical tests were performed as fermentation with five basic sugars and thereby production of acid or gas. Subculturing of the colonies was performed to obtain pure culture and finally the organisms were identified without typification.

Pathological findings

The *in vivo* and *in vitro* gross pathological characteristics of the affected portions were recorded during clinical examination (Table 5). The amputated parts were preserved at 10% formalin solution. A part of each sample of the formalin fixed udder tissues was subsequently processed for paraffin embedding, sectioned and stained with haematoxylin and eosin as per standard procedures (Luna, 1968) for the histopathological examinations. The lesions were recorded and histopathologically categorized according to the degree of severity of the lesions.

Surgicotherapeutical findings

Preparation and Surgical operation

The animals accepted for the surgical intervention were prepared considering anaesthesia, cleaping and shaving, disinfecting, selecting operation sites and areas, health status of the patients, sterilized instruments and appliances as well as preparation of the surgeons. The selected gangrenous portions were surgically removed, fluid therapy was managed and the effective measures on checking bleeding were taken during the course of surgical operation

following the standard methods (O'Connor, 1980; Weaver, 1988). During the surgically removal of the gangrenous portions, the holes of varying degrees in sizes and depth were made. Necrosed tissues (blackish discoloration) were removed until the normal tissues (somewhat pink in colour with minimal blood oozing) were seen. The fluid and exudates were removed from the pockets by soaking with sterile gauze. After the complete removal of the exudates, penicillin-streptomycin combination (Streptopen^R, Renata Animal Health, Bangladesh) was applied locally first, then pockets were filled up by the gauze soaked with tincture of iodine as counter irritant. Suture was made keeping a minimal opening to continue the daily change and dress by new ones.

Postoperative management

The animals were kept in the hospital for 3-5 day under strict observation. Fluid therapy was performed to maintain electrolytes and energy loss. Antibiotic course with penicillin-streptomycin combination (Streptopen @ 2.5 gram per 100 kg of body weight daily for five days) was suggested without conducting any antibiotic sensitivity test. The wound was cleaned and dressed daily with gauze soaked with tincture of iodine as counter irritant and removed the previous one and continued until a suitable condition. The wound was protected from maggot formation by applying of oil of turpentine-chloroform solution surrounding the wounds and also careful attention was given to prevent secondary injury. Nutritious feed, comfort and bedding, vitamin mineral supplementation and hygienic environment were emphasized for enhancing the healing process. The prognosis of surgicotherapeutical attempts was observed periodically.

RESULTS AND DISCUSSION

Clinical findings

The number of clinical cases, number of affected teats and/or quarter and the clinical signs of the mastitic cows along with their causative bacterial organisms are listed in Table 1.

Table 1. Clinical history and signs of the mastitic cows observed

Isolated organism	No. of clinical cases	No. of quarter (s) affected	Clinical signs of the mastitic cows
<i>Staphylococcus spp.</i>	3	2 in 1 and 1 in 2 cases	Severe systemic and local reactions Cardinal signs of inflammation locally Partial to complete anorexia, fever, profound depression, ruminal atony, recumbency
<i>Escherichia coli</i>	2	1 in 1 and 4 in 1 case	Severe systemic and local reactions High fever, anorexia, watery diarrhoea, dehydration, depression, shivering, and rapid loss of body weight
<i>Staphylococci, Clostridia, E. coli</i>	1	1	High fever, anorexia, depression, shivering, and rapid loss of body weight
<i>Bacillus spp.</i>	1	1	Anorexia, high fever, depression, and recumbency

Microbiological findings

The Cultural colony characteristics and Gram's staining reaction and biochemical properties of the organisms isolated from the gangrenous tissues and exudates are listed in Table 2, Table 3 and Table 5.

Table 2. Cultural colony characteristics and Gram's staining reaction of the organisms isolated from the gangrenous tissues and exudates

Nutrient agar	Blood agar	Staphylococcus Media No. 110	MacConkey agar	EMB agar	SS agar	Shape	Arrangement	Gram's staining	Isolated
Gray white or yellowish colony	White to golden yellow	Golden colour colony	No growth	No growth	No growth	Cocci	Cluster	+ ve	<i>Staphylococcus spp.</i>
Smooth white to grayish white colony	Produced haemolysis	No growth	Rose pink lactose fermented colony	Yellow green metallic sheen	Pink colour colony	Short plump rod	Singly, paired, short chained	- ve	<i>Escherichia coli</i>
Grayish white or cream coloured colony	Creamy yellow coloured colony	No growth	No growth	No growth	No growth	Rod with square ends	Singly, paired, long chained	+ ve	<i>Bacillus spp.</i>
Round, grayish, semitranslucent, smooth with an entire edge	Irregular zone of haemolysis and an outer zone of discoloration and partial haemolysis					Short, almost coccal forms	Singly, paired, short chained	+ve	<i>Clostridium Spp.</i>

Table 3. Biochemical characteristics of the organisms isolated from the gangrenous tissues and exudates

Isolated organisms	Fermentation properties with carbohydrates					Catalase test	Coagulase test	Indol production test	Methyl red test
	D	M	L	S	Mn				
<i>Staphylococcus spp.</i>	+A	+A	+A	+A	+A	+	+	-	-
<i>Escherichia. coli</i>	+A	+A	+A	+A	+A	+	-	+	+
<i>Bacillus spp.</i>	+A	+A	+A	+A	+A	+	-	-	-
<i>Clostridium Spp.</i>	+AG	+AG	+AG	+AG	-				

+ = Positive reaction, - = Negative reaction, A = Acid production, G = Gas production, D = Dextrose, M = Maltose, L = Lactose, S = Sucrose, Mn = Mannitol

Pathological and surgicotherapeutical findings

Table 4. Isolated organisms, gross morbid and histopathological as well as therapeutic findings of the clinical cases including their prognosis

Isolated organism	Gross lesions	Histopathological lesions	Therapeutic measures	Prognosis
<i>Staphylococcus spp.</i>	Coldness of the affected areas, blue-blackish discolouration of the affected portion, hard and sore to touch, serosanguineous fluid exudation, gas formation and crepitation on palpation, severe lameness on the affected side, sloughed epidermal layers	Severe coagulation necrosis in the parenchymatous tissues and thrombosis of the veins, focal epithelial erosion and ulceration in the ductal system, neutrophilic infiltration in the subepithelial spaces, pink staining proteinaceous exudates in the milk alveoli	Penicillin and streptomycin combination (Streptopen-Renata @ 2.5 gram per 100 kg body weight intramuscularly daily for 5-7 days), fluid therapy (dextrose and electrolytes), diclofenac as antiinflammatory agent (Diclovet), tetanus toxoid	Best
<i>Escherichia coli</i>	Extremely swollen of the affected quarter(s), the gangrenous portions were cold to touch and insensible to pain, the cardinal signs of inflammation (redness, swelling, heat, pain) were found in surrounding living tissues	Hyperemia, haemorrhage and oedema of the affected areas with thrombosis in blood vessels, intense neutrophilic infiltration, subepithelial oedema and hyperplasia and disorganization of the epithelia of the ducts	As above	Good for one case but another one died
<i>Staphylococcus cci</i> , <i>Clostridia</i> , <i>E. coli</i>	Coldness of the affected areas, blue-blackish discolouration of the affected portion, hard and sore to touch, serosanguineous fluid exudation, gas formation and crepitation on palpation, severe lameness on the affected side, sloughed epidermal layers	Focal epithelial necrosis, erosion and ulceration in the ductal system, microthrombi in the blood vessels, epithelial hyperplasia and disorganization, subepithelial oedema with intense reactive cells infiltration, pink staining proteinaceous exudates in the milk alveoli	As above	Better
<i>Bacillus spp.</i>	The affected portion was discoloured, cold, sloughing out in affected quarter	Epithelial necrosis and desquamation with huge reactive cells in the subepithelial spaces of the ducts,	As above	Best

Gangrenous mastitis in cows was investigated and the animals brought to clinics for the diagnosis and treatments were examined clinically, pathomicrobiologically and surgicotherapeutically. Out of 29 mastitis cases, only 7 cases of gangrenous mastitis were recorded and out of 7 cows with gangrenous mastitis, 5 indigenous and 2 crossbred, aged approximately between 3.5-6 years, brought for the diagnosis and treatment were screened for udder lesions.

The clinical manifestations of the affected animals (Table 1) varied minutely from individual to individual and this may be due to the variable course of the disease, but generally described as fever, anorexia, gradual loss of performances, depression, and reluctance to move. Diarrhoea with the development of severe systemic signs (shivering, trembling) was exclusively found in cows with coliform mastitis which may be due to enterotoxigenic (diarrhogenic) activity of the organisms and the liberation of endotoxins in blood. These organisms were readily come in contact with the udder with faecal contaminants and causing mastitis (Radostits *et al.*, 2000). Rapid multiplication of the coliforms in udder occur and the induction of inflammation that subsequently destroys the organisms, thereby releasing endotoxins. The resulting toxemia produces severe local and systemic signs of acute or peracute mastitis including gangrenous one occasionally (Fraser *et al.*, 1998). The *streptococci* with or without in

association with *E. coli* and *Clostridium spp.* produces peracute mastitis and *Bacillus spp.* cause acute haemorrhagic or gangrenous mastitis (Radostits *et al.*, 2000).






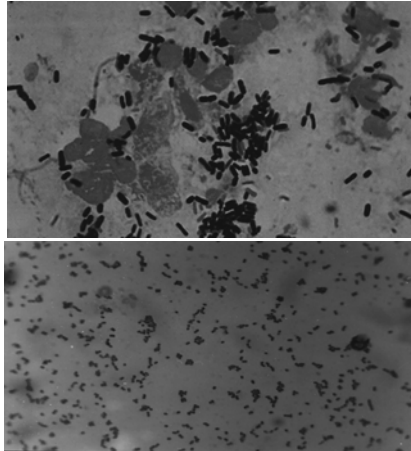
The onset of the disease may not be associated only with the isolated bacteria, but also various risk factors such as pathogen risk factors (toxins, antigenic variation), host risk factors (age, physiological state, stage of lactation and defensive mechanisms), environmental risk factors (faecal contamination, poor hygienic measures) as well as the lacking of farmer's awareness about timely diagnosis and treatment (Radostits *et al.*, 2000) which possibly rendered the development of gangrene.

Visible gross pathological characteristics of the gangrenous mastitis in all cases (Table 4) were similar except in the number of quarters affected and the degree of sloughing out of the tissues. The general gross characteristics were as variable degrees in discolouration, extremely swollen, coldness and painless of the affected portions, odouriferous serosanguineous exudation and presence of a line of demarcation but the cardinal signs of acute inflammation (redness, swelling, heat and pain) were observed in the surrounding living tissues of the udder. The number of quarters affected and the degree of sloughing out of the gangrenous tissues may be due to the variation in the course of disease. Despite the differences in the gross lesions no apparent variation was found during the histopathological examination and the lesions were overall characterized as necrosis, erosion and ulceration of the ductal epithelia, huge neutrophilic infiltration in the subepithelial areas, pink staining proteinaceous materials in the milk alveoli, and a zone of inflammation characterized by the presence of dilated and congested blood vessels, reactive cells. This was typically described by many authors elsewhere (Jubb and Kennedy, 1963; Sastry, 1983; Thomson, 1988; Jones *et al.*, 1997).

Cultural and staining characteristics of the bacteria isolated from the mastitic cows and their biochemical properties are presented in Table 2, Table 3 and Table 5, respectively. All isolated bacteria produced characteristic colonies in nutrient and blood agar media but variable results were found in other agar media. *E. coli* produced identical colonies in MacConkey, EMB and SS agar; staphylococci in Staphylococcus Media No. 110, but no growth of all isolates was recorded in different agar media (Table 2). All isolates were Gram positive except *E. coli*. The different isolates showed identical result in different biochemical tests including sugar fermentation, catalase, coagulase, indol production and Methyl red tests. Hossain *et al.*, (2002) reported the similar results produced by the isolated staphylococci, *E. coli*, Bacilli on working with the enterobacteria from diarrhoeic calves.

The clinically affected animals were accepted for surgical operation as per standard procedure in order to amputate the gangrenous portion to stop the further spread. The operation was done taking possible hygienic measures and careful attention was given during the postoperative management to avoid the further deterioration of the health. Fluid therapy to correct energy and electrolytes loss, antiinflammatory agent (diclofenac) to minimise the postoperative pain, tetanus toxoid to avoid the development tetanus was suggested along with the course of antibiotic (penicillin-streptomycin combination without determining antibiotic sensitivity test) as per recommended suggestion (Radostits *et al.*, 2000). One affected cows was died during the course of postoperative treatment and this may be endotoxic shock or severe systemic reaction due to endotoxaemia. Fluid therapy was performed extensively to eliminate the toxic metabolites. The successful operation and the effective postoperative measures had possibly showed the favourable prognosis.

Table 5. Different characteristic features of gangrenous mastitis in cows

		
<p>Gangrenous quarter characterized by blackish discoloration</p>	<p>Dark blackish discoloration of the milk oozing from the affected quarter</p>	<p>Dissected quarter</p>
		
<p>Cutaneous erosion and ulceration at the base of the affected teat</p>	<p>Blackish discoloration of the parenchymatous tissues indicating gangrene</p>	<p>Gram positive bacteria (Top: Bacilli and Bottom: Cocci)</p>

During the course of surgical operation, moderate degree of bleedings were occurred and checked by ligating of all major blood vessels with the strong absorbable suturing materials (Singh *et al.*, 1996) and crushing by artery forceps following as per recommended procedure (O'Connor, 1980). Almost all necrosed tissues were removed and gauze soaked with a counter irritant was plugged immediate after locally administration of penicillin-streptomycin combination (Streptopen @ as per requirements) to enhance healing and resist further bacterial multiplication. The course of parenteral antibiotic therapy (Streptopen @ 2.5 gram per 100 kg of body weight daily for 5-7 days intramuscularly) was confirmed and dressing was performed in every alternative days for 7 days. Tetanus toxoid to prevent tetanus, protective covering over the opening, fly repellent (oil of turpentine and chloroform solution) surrounding the lesions were ensured. Supply of nutritious feed, hygienic place and comfort bedding, electrolytes therapy for 5 days were suggested. The duration of healing was variable and this might be due to the degree of wounds and health status.

CONCLUSION

Investigation of gangrenous mastitis in cows based on the findings as stated above will certainly help in proper diagnosis of the disease which is sporadically found in Bangladesh and causes economical loss to the farmers. So, this study will also help to dictate specific medication as well as to take proper prevention and control strategies.

REFERENCES

Carlton, W.W. and McGavin, M.D. 1995. Thomson's Special Veterinary Pathology. 2nd edition. Mosby, New York. USA

- Cowan, S.T. 1985. *Cowan and Stell's Manual for Identification of Medical Bacteria*. 2nd edn. Cambridge University Press, Cambridge, London.
- Fraser, C.M., Bergeron, J.A. and Aiello, S.E. 1998. *The Merck Veterinary Manual. A Handbook of Diagnosis, Therapy, and Disease Prevention and Control for the Veterinarian*. (Eighth Edition). Merck & CO., Inc. press, U.S.A.
- Hossain, K.M.M., Saha, S., Samad, M.A. and Choudhury, K.A. 2002. Isolation and characterization of Enterobacteria from diarrhoeic calves with their pathogenicity in mice and in-vitro sensitivity to antibiotics. *Bangladesh Veterinary Journal*. 36 (1-2): 43-49
- Jones, T. C., Hunt, R. D. and King, N. W. 1997. *Veterinary Pathology*. Williams and Wilkins, Baltimore.
- Jubb, K. V. F., Kennedy, P. C. 1963. *Pathology of Domestic Animals*. Academic Press, New York and London
- Luna, L.G. 1968. *Manual of Histologic Staining Methods of the Armed Forces Institute of Animals*, 3rd edition. McGraw-Hill Book Company. New York.
- McLeod, W.G., Rowland, A.C. and Sewell, M.M.H. 1981. *Handbook of tropical Veterinary Laboratory Diagnosis*. Centre for Tropical Veterinary Medicine University of Edinburgh.
- O'Connor, J. J. 1980. *Dollar's Veterinary Surgery*. 1st Indian Edition C.B.S. Publishers and Distributors, Delhi.
- Radostits, O.M., Blood, D.C., Gay, C.C., and Hinchcliff, K.F. 2000. *Veterinary Medicine: A Textbook of the Diseases of Cattle, Sheep, Pigs, Goats and Horses*. 9th edition. WB Sanders. London.
- Sastry G.A. 1983. *Veterinary Pathology*. 6th edition. CBS Publishers and Distributors. Delhi.
- Singh, J., Singh, P. and Arnold, J.P. 1996. The Mammary glands. In: *Ruminant Surgery*. 1st edition. Edited by R.P.S. Tyagi and Jit Singh, C.B.S. Publishers and Distributors, Delhi.
- Thomson, R.G. 1988. *Special Veterinary Pathology*. 2nd edition. B.C. Decker, Inc. Philadelphia.
- Weaver, A.D. 1988. *Bovine Surgery and Lameness*. 1st edition. English Language Book Society. Oxford.