ANALYSIS OF PREVALENCE OF INFECTIOUS BURSAL DISEASE IN BROILER FLOCKS IN DINAJPUR

M. SAIDUR RAHMAN*[1], M. SADEQUL ISLAM[1], M. T. RAHMAN[2], N. H. PARVEZ[2], M. M. RHAMAN[1]

[1] MS student, Department of Anatomy and Histology, Hajee Mohammad Danesh Science and Technology University (HMDSTU),
[2]Assistant professor, Department of Anatomy and Histology, Faculty of Veterinary and Animal Science, HMDSTU, Bangladesh.

Accepted for publication: 12 January 2010

ABSTRACT

Rahman, M.S., Islam, M.S., Rahman, M.T., Parvez, N.H, Rahman, M.M. 2010. *Analysis of prevalence of infectious Bursal disease in broiler flocks in Dinajpur***.** Int. J. Sustain. Crop Prod. 5(1)15-18.

The study was conducted in fourty broiler farms of Dinajpur district for the determination of infectious bursal disease (IBD) during the period of 20th November to 30th December 2009. On the basis of history and postmortem pathological lesions, the prevalence of IBD was 7.13%, 7.19%, 5.97% and 6.46% in Kotwali, Kaharol, Birgonj and Birol thanas respectively. The mortility was 3.73% in Kotwali, 3.39% in Kaharol, 4.33% in Birgonj, 4.39% in Birol thanas. The highest prevalence was found in Kaharol and lowest was found in Birgonj. The highest mortality was found in Birol thana. The main pathological lesions observed in this study were hemorrhages on thigh and brest muscles; inflamed, edematous, hyperemic and atrophied with haemorrhagic bursa of fabricious and in some cases kidneys were found swollen. The study also showed that the broilers of four weeks of old were highly susceptible to IBD (55%) whereas in third week 12.5% and in fifth week 32.5% and the broilers of two weeks of age were not affected with IBD.

Keywords: *Broiler, Infectious Bursal Disease, Prevalence, Dinajpur.*

INTRODUCTION

The name "Gumboro" disease was initially given to the condition because it was first recognize on the farm in the Gumboro district of Delawre, USA in 1962. Initially the IBD was confused with a variant form of infectious bronchitis virus (IBV) accompanied by nephrosis (Winter and Hitchner, 1962; Cosgrove, 1962). Winter field *et al* (1962) succeeded in isolating an agent in embryonating eggs and the isolate was referred to as "Infectious bursal agent". Hyper virulent IBDV strains were first reported in Belgium and Netherlands in 1987. Presently IBDV has a worldwide distribution, occurring in all major poultry producing areas (Sjaak Wit and William Baxendale, 2004). The distinct lesions are found in exposure to IBDV only in the chicken. Mainly the infection occurred through oral ingestion of contaminated feed and other organic materials.

Gumboro, the highly infectious disease of poultry causing highest mortality per year by destroying immune system despite vaccination in Bangladesh. The prevalence of the disease was found in both private and government sectors. In the previous year the severity of the disease was particularly high in egg producing farms than the broiler. Both in vaccinated and non-vaccinated farms the IBD outbreaks in several areas in Bangladesh are found. It is true that the farmers are not properly aware about the AIDS like disease, IBD. So a systemic work should be developed on the incidence and prevalence on Infectious bursal disease.

MATERIALS AND METHODS

The clinical and postmortem examinations were performed for diagnosis of infectious bursal disease at veterinary teaching hospital of Hajee Mohammad Danesh Science and Technology Unuversity, Dinajpur. Dead birds brought by the farmer and some sample collected from various farms of Kotowali, Kaharol, Birgonj and Birol thanas of Dinajpur district were diagnosed. Fourty cases of gumboro were diagnosed between 20th November to 30th December 2009 and the study was performed only in broiler.

Clinical examination

a) History

Under this point the following data was collected from the farmers:

Name of farmer, name of area, total number of birds in farm, total number of affected birds, daily mortality and total mortality. During the period present and previous history was taken from each farmer.

*Corresponding Author: Dr. Md. Sadequl Islam, Email: sad_biit08@yahoo.com; Mobile: 01721417598

b) General examination

At first the external appearance of the bird was observed then general condition of the chicken, condition of vent, feathers. Presence or absence of diarrhea was also marked.

Postmortem examination

It was conducted with the help of rubber gloves, a pair of shears, scissors, knife, scalpel and forceps.

Technique

At first the chicken was laid on its back and each leg to expose the internal organs, in turn drawn outward away from the body while the skin was incised between the leg and abdomen on each side. Then the both legs were grasped firmly in the area of the femur and bent forward, downward and outward, until the head of both femurs were broken free of the acetabular attachment so that both legs lied flat on the table. The skin was cut between the two previous incisions at a point midway between keel and vent. The cut edge was then forcible reflected forward, cutting was necessary, until the entire ventral aspect of the body including the neck, was exposed. For exposing of the viscera, knife was used to cut through the abdominal wall transversely mid-way between the keel and vent, then through the breast muscle on each side. Positioning shears were used to cut first the rib cage, the coracoids and clavicle on both side. With some care this was done without severing the large blood vessels. The location of the bursa of fabricious is on the dorsal aspect of the cloaca. Through examination of the organs was done.

RESULTS

For the conformation of Infectious bursal disease the pathological lesions of different parts of the body were examined mainly on bursa of fabricious and thigh muscle. The postmortem changes found in different organs are; hemorrhages were present on the pectoral (Photograph 1 and 2) and thigh muscles (Photograph 3), kidneys were swollen. The main lesions, enlarged and edematous bursa of fabricious (Photograph4) were found in primary stage.

The present study was conducted in fourty different poultry farms of four thanas of Dinajpur district. The total number of bird were 52050.The prevalence of IBD was 7.13%, 7.19%, 5.97% and 6.46% in Kotwali, Kaharol, Birgonj and Birol thanas respectively. The mortility was 3.73% in Kotwali, 3.39% in Kaharol, 4.33% in Birgonj, 4.39% in Birol thanas. The highest prevalence was found in Kaharol and lowest was found in Birgonj (Figure1). The highest mortality was found in Birol thana. While no case was found in first two weeks of age and the broilers of four weeks of old were highly susceptible to IBD (55%) whereas in third week 12.5% and in fifth week 32.5% (Table 1).

Table 1. Number of dead birds, Total mortality, Daily Mortality, Number of affected bird and Prevalence (%) of four different Thanas of Dinajpur District

Name of thana's	Total number of birds	Number of dead bird	Total mortality (%)	Daily Mortality		Number of affected bird	Prevalence (%)
				Minimum	Maximum		
Kotwali	11700	436	3.73	5	173	9837	7.13
Kaharol	11750	398	3.39	3	149	9937	7.19
Birgonj	14350	621	4.33	8	160	12353	5.97
Birol	14250	624	4.39	6	159	13071	6.46
Total	52050	2079	3.99	-	-	45198	26.75

DISCUSSIONS

The present work was carried out to find out the reliable information related with actual status of prevalence, mortality, morbidity and pathological lesions of infectious bursal disease (IBD) in broiler in Dinajpur district of Bangladesh. In this study the diagnosis of IBD was made on the basis of the farm history and gross pathological lesions as had been diagnosed by Raj Wali Khan, *et.al.* (January, 2009).

Raj Wali Khan, *et.al.* (January, 2009) examined that at necropsy the gross pathological lesions were dehydration and darkened carcass, hemorrhages were present on pectoral, leg and thigh muscles. The kidneys were swollen and a gelatinous film was present around the bursa. In this study the gross pathological lesions observed on necropsy examination were hemorrhages on thigh (Figure 3) and breast muscles (Figure1 and 2); inflamed, edematous, hyperemic and atrophied with haemorrhagic bursa of fabricious (Figure 4 and 5) and in some cases kidneys were found swollen.

Khan, *et al.* (2009) reported that IBD affected birds were four weeks old conclusively. Rajaonarison *et al.*, (2006) showed that the birds of three to five weeks of old were most susceptible to IBD. In the present study the most affected birds were four weeks old which is similar to that of Khan (2009).

Wyeth *et al*., (2003) carried out studies IBDV in Great Britain and examined that IBDV can infect some chicks as young as fifteen days old. In this study no bird was found affected up to fifteen days. Richard and Miles, (2004); Butcher, (2003); Savova and Liupkel (2002); and Chettle *et al*., (1999) examined that subclinical form of IBD in chicken took placed in less than three weeks of age. In the present study no subclinical form was examined in two weeks of old Broilers.

Sanchez *et al*., (2005) determined the acute clinical IBD in broiler chicken farm in Denmark. The analysis was performed using data from all broiler farm located in the Jutland peninsula and the island of funen (168 municipalities). The moran's index 1, K-functions and scan statistics were used to describe the dynamics of the epidemic and a total fourty three farms were used for research purpose infected with IBD. The present study was carried out in district dinajpur in four thanas. Fourty different broiler farm affected with IBD was selected for research purpose and all the data were analyzed by using scientific calculator (CASIO scientific calculator *fx*-100MS).

Figure 1. Hemorrage in Pectoral Muscle

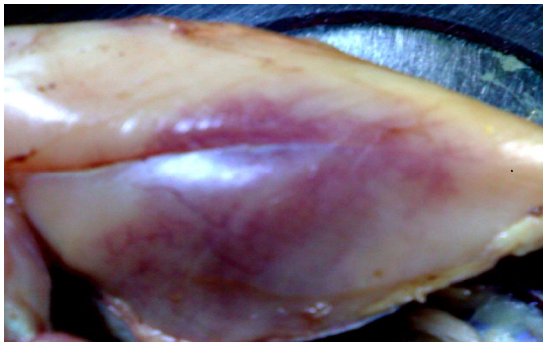

Figure 2. Hemorrage in Pectoral Muscle

Figure 3. Thigh muscle of 28 days old broiler chicken consisting hemorrhages

Figure 5. A cut surface of bursa of fabricious of 22 days old broiler showing petechial hemorrhages



Figure 4. The internal surface of bursa of fabricious of 28 days old broiler with gelatinous materials

REFERENCES

Butcher.2003.Pathogenesis of IBD in commercial broiler flock. IFAS, Florida,32611.

Cosgrove A., 1962. An apparently new Diease of chickens-Avian nephrosis. Avian Dis.6: 385-389.

Gary D. Butcher, Richard D and Miles.2003. Poultry Nutritionist, Cooperative Extension service, Institute of food and Agriculture Sciences, University of Florida, Gainesville-32612.

Hitchner S.B(1970). Infectivity of Infectious bursal diseae Virus for embryonating eggs. Poult. Sci. 49: 511-516.

Khan R.W.,Khan F.A., Farid K., Khan I., Tariq M. January 2009. Prevalence of Infectious Bursal Disease in Broiler in District Peshawar.ARPN Journal of Agricultural and Biological science. Vol.4,No.1.

Rajaonarison J.J. Rakotonindrina, S.M.Rakotondramary, E.K. and Razafimanjary. S. 2006. Gumboro Disease(Infectious bursitis) in Madagascar. Rev Elev Med Vet Pays Trop. 47(1):15-17.

Richard and Miles. 2004. Department of Dairy and Poultry Science, Cooperative Extension service, University of Florida, Gainesville-32616.

Sanchez J. Stryhn, H. Flensburg, M. Ersboll, A.K. and Dohoo, I.2005. Analysis of the 1999 outbreak of acute clinical infectious bursal disease in Broiler flocks in Denmark. Prev Vet Med.71(3-4): 209-23.

Savova M. and V. Liupkel. 2002. Asymptomatic course of infectious bursitis in Chicks. Vet Med Nauki.21(10): 95-101.

Winterfield W.R. Hitchner SB. Appleton GS and Cosgrove AS(1962). Avian nephrosis, Nephritis and Gumboro disease. N & M News Views 3: 103.

Wit, J. J. and William Baxendale.2004. The Infectious bursal diseses.Website www.gumboro.com©Intervet 2004.

Wyeth P.J.,N.J.Chettle and A.R.Mohepat.2003. Infectious bursal disease in Great Britain. Vet. Rec.130:30-32.