Int. J. Sustain. Crop Prod. 5(1):11-14(January 2010)

MORPHOMETRIC ANALYSIS OF VESICULAR GLANDS OF INDIGENOUS BULL

M. SAIDUR RAHMAN[1], M. SADEQUL ISLAM[1], M. T. RAHMAN[2], N. H. PARVEZ[2], M. M. RHAMAN[1]

[1] MS student, Department of Anatomy and Histology, Hajee Mohammad Danesh Science and Technology University (HMDSTU),
[2]Assistant professor, Department of Anatomy and Histology, Faculty of Veterinary and Animal Science, HMDSTU, Bangladesh

Accepted for publication: 12 January 2010

ABSTRACT

Rahman, M.S., Islam, M.S., Rahman, M.T., Parvez, N.H, Rahman, M.M. 2010. *Morphometric analysis of vesicular glands of indigenous bull.* Int. J. Sustain. Crop Prod. 5(1):11-14.

The morphometric analysis of the vesicular glands of indigenous bull in Bangladesh was studied. The experiment was conducted in the laboratory of Anatomy under the Department of Anatomy and Histology during the period from April to July, 2009. Vesicular glands of the indigenous bull of same ages were found to differ in length, breadth, thickness and weight. The average length, breadth, thickness and weight of the right gland were 9.44 cm, 2.78 cm, 1.45 cm, 19.90 gm respectively, which are higher than those of left gland. In case of four years old bull the length, breadth, thickness and weight of vesicular glands were found highest than those of the two and three years old bull. 0.12 mm distance between the opening of the duct of vesicular gland and ductus deferens was present. Both the ducts of vesicular gland and ductus deferens open 0.25 mm away from the ventro-lateral aspect of the urethral canal as common opening. The duct of vesicular gland opens 2.5 cm caudal to the opening of the urinary bladder. This study revealed that the length, breadth, thickness and weight of the vesicular gland varied among the different indigenous bull and also in the right and left vesicular gland of the same bull.

Key words: *Morphology, Vesicular gland, Indigenous, Bull.*

INTRODUCTION

Indigenous bull is the heritage and an important asset of Bangladesh, found all over the country. They have tremendous demand in every part of the country for their strength and resistance against different diseases. In bulls, the vesicular gland is a compact, lobulated organ. Intralobular secretory duct drain the slightly coiled tubular portions if the tubuloalveolar gland and, in turn, are drained by the main secretory duct. The secretory columnar cells have small lipid droplets and glycogen and give a positive alkaline phosphatase reaction. The basal cells are characterized by large lipid droplets. Approximately 50% of the lipid materials are cholesterol and its esters, approximately 25% is triglycerides, and approximately 10 % is phospholipids. The gelatinous, white, or yellowish-white secretory product of the vesicular gland is rich in fructose which serves as an energy source for ejaculated spermatozoa (Dellmann and Eurell, 1998). Mary et. al, (1961) reported that testosterone and androstenedione in the testes, and of fructose and citric acid in the seminal vesicles, were related to results of gross anatomical and histological measurements of testes and vesicular glands. They also established a significant correlation between the growth and secretory activity of the seminal vesicles and the diameter of the seminiferous tubules in bull testes. So the morphometric analysis of the vesicular glands bears great importance. From these points of view the present study was conducted.

MATERIALS AND METHOD

The study was carried out on 14 bulls in the Anatomy laboratory under the Department of Anatomy and Histology, Hajee Mohammad Danesh Science and Technology University, Dinajpur on April to July, 2009. The vesicular glands were collected from the lateral aspect of the terminal part of each ductus deferens of 14 different bulls from various slaughter houses of Dinajpur district in between the age of two to three years. The length and breadth of the vesicular glands were measured by using centimeter scale. Thickness and diameter were measured by using slide calipers and weight was measured by using electric balance.

$$d=d^{/} - (\pm e)$$

d=diameter, $d^{/}$ = relative diameter (M+F), M=Main scale reading, F=V×VC where F= Vernier scale reading, V= Vernier equilibrium, VC= Vernier constant, e = Instrumental error. The opening of the vesicular duct and ductus deferens were determined by giving longitudinal incision on ventral aspect of the penis. The distance between the opening of vesicular duct and ductus deferens were measured by using millimeter scale. The similar work was performed in both left and right glands. Each of the fourteen bulls was indicated as an individual sample and data were collected from each bull.

RESULT AND DISCUSSION

The vesicular glands are compact glandular organs with a lobulated surface. In the present study they measured average 9.44 cm in length, 2.78 cm in breadth, 1.45 cm in thickness and 19.90 gm in weight of right vesicular gland whereas the left one was measured 8.58 cm in length, 2.41 cm in breadth, and 1.30 cm in thickness and 18.46 gm in weight.

Whittier (1993) reported that the seminal vesicles consist of two lobes about 4 to 5 inches long, each connected to the urethra by a duct. In the present study the average length was found 9.44 cm (3.72 inches) and 8.58 cm (3.38 inches) of right and left vesicular gland respectively. The vesicular gland and ductus deferens (Annexure 1 Photograph 1 & 2) opens 0.25mm away from the ventro-lateral aspect (seminal colliculus) of the urethral canal as common opening.

Getty (1975) showed that vesicular glands in adult bull are about 10 to 12 cm in length and 3 cm in breadth whereas the recent study revealed that the average length and breadth of right vesicular gland were 9.44 cm and 2.78 cm; In case of left vesicular gland average length and breadth were 8.58 cm and 2.41 cm respectively.

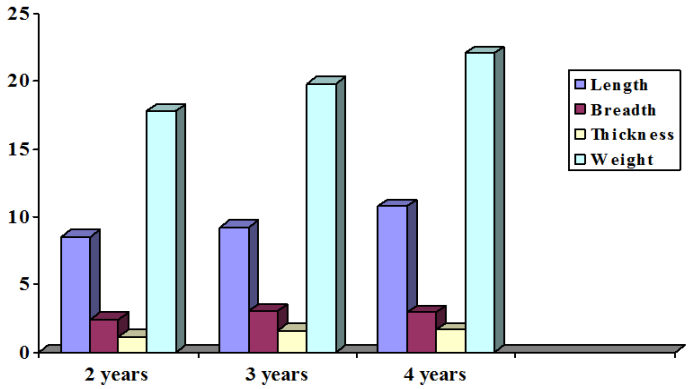

Figure 1. Graphical representation of average length, breadth, thickness and weight of Right vesicular gland of bull at different ages

Hafez (1962) stated that the length, breadth, thickness and weight were 13 cm, 3 cm, 2 cm and 75 gm (left and right vesicular gland combinedly). In this study the average length, breadth, thickness and weight were found 9.44 cm, 2.78 cm, 1.45 cm and 19.90 gm in case of right vesicular gland and 8.58 cm, 2.41 cm, 1.30 cm and 18.46 gm in case of left vesicular gland (Table. 1). In four years old bull the average length, breadth, thickness and weight of left vesicular gland were found 9.93 cm, 2.46 cm, 1.51 cm and 19.12 cm respectively and in case of right vesicular gland the average length, breadth, thickness and weight were 10.77 cm, 2.91 cm, 1.63 cm and 22.07 cm respectively which were highest than those of the two and three years old bull (Figure 1 and 2). The study also showed that the right vesicular gland was more in length, breadth, thickness and weight than those of the left vesicular gland (Annexure 1 Photograph 4). The excretory duct opens at the seminal colliculus just lateral to the ductus deferens (Getty, 1975). In the seminal colliculus (Annexure 1 Photograph.1 and 3) 0.12 mm distance was noted between the openings of vesicular gland and ductus deferens. The dorsal surface of each faces dorsally and

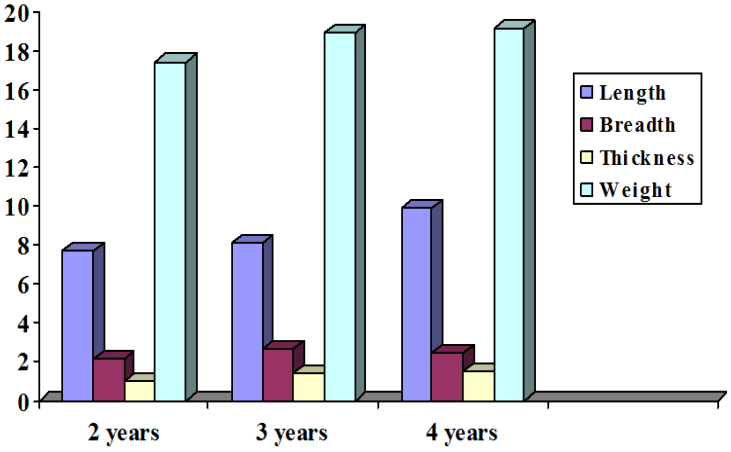

Figure 2. Graphical representation of average length, breadth, thickness and weight of left vesicular gland of bull at different ages

medially and is partially covered with peritoneum. The ventral surface faces in the opposite direction and is nonperitoneal. Each may be regarded as consisting of very thick-walled, sacculated tube, bent on itself in a tortuous manner. They are commonly unsymmetrical in size and shape.

Table 1. Average Length, breadth, thickness and weight of the vesicular glands

Average	**Right vesicular gland**	**Left vesicular gland**
Length (cm)	9.44	8.58
Breadth (cm)	2.78	2.41
Thickness (cm)	1.45	1.30
Weight (gm)	19.90	18.46

Though the vesicular gland is an accessory gland but it bears important role in semen quality. The secretion of fructose and citric acid, the vital components of the semen greatly depend on the size of the vesicular gland. Such type of work did not performed in indigenous bull in Bangladesh. So further study on cellular and molecular level bears great significant.

REFERENCES

Dellmann, H.D and J. Eurell, 1998. Veterinary Histology. Fifth Edition.

Getty R. 1975. Sisson and Grossman's The Anatomy of the Domesticated Animals. Fifth Edition.

Hafez, E.S.E., 1987. Reproduction in Farm Animals. Fifth Edition.

Mary F. Hay, H. R. Lindner and T. Mann 1961. Morphology of Bull Testes and Seminal Vesicles in Relation to Testicular Androgens. The Royal Society.

Whittier Jack C. 1993. Reproductive Anatomy and Physiology of the Bull, University of Missouri Extension.

ANNEXURE 1

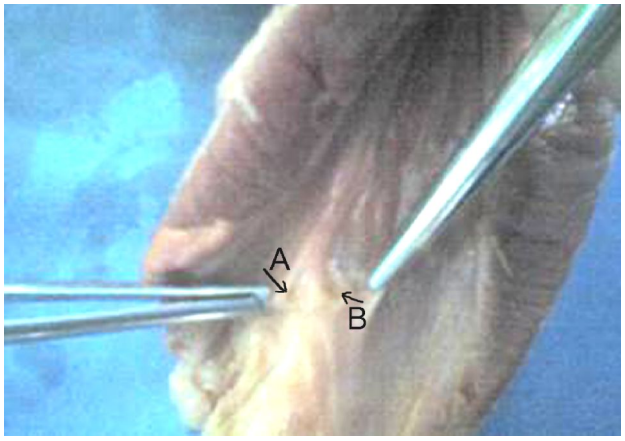

Photograph 1: Openings of vesicular glands (A & B)

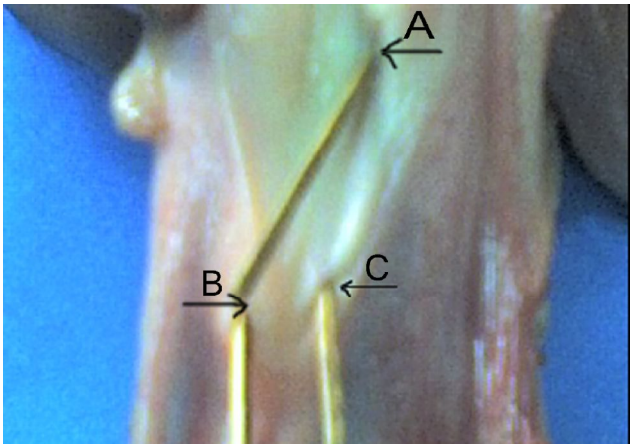

Photograph 2: Two openings of ductus deferens (B & C), urethral opening (A)

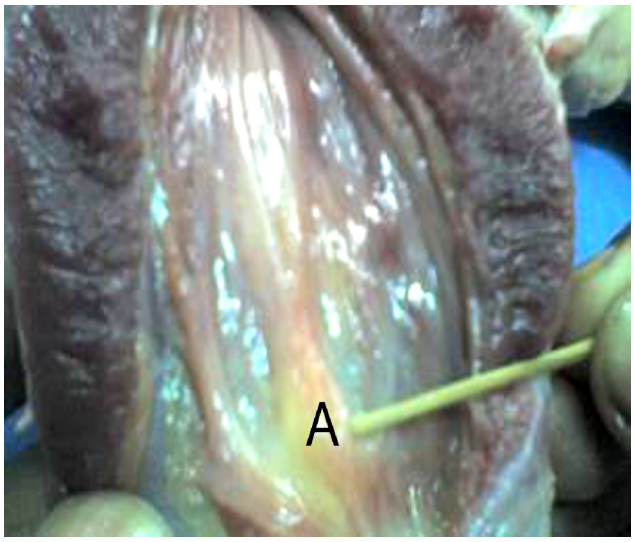

Photograph 3: Seminal colliculus(A), a common area for the opening of ductus deferens and vesicular glands

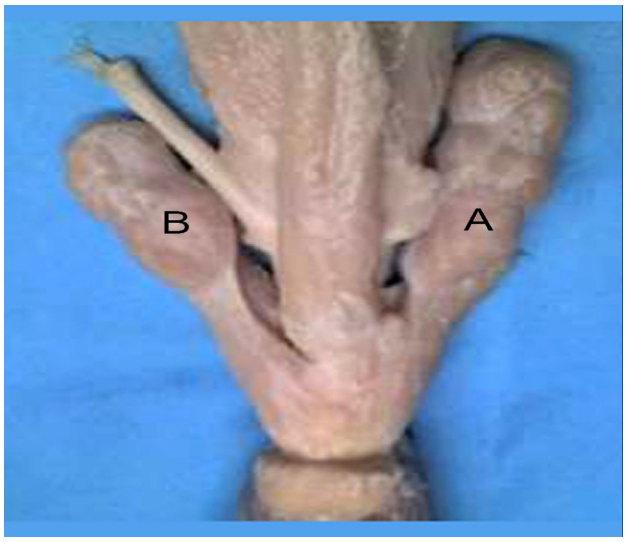

Photograph 4: Right vesicular gland (A) and Left vesicular gland (B) of Bull